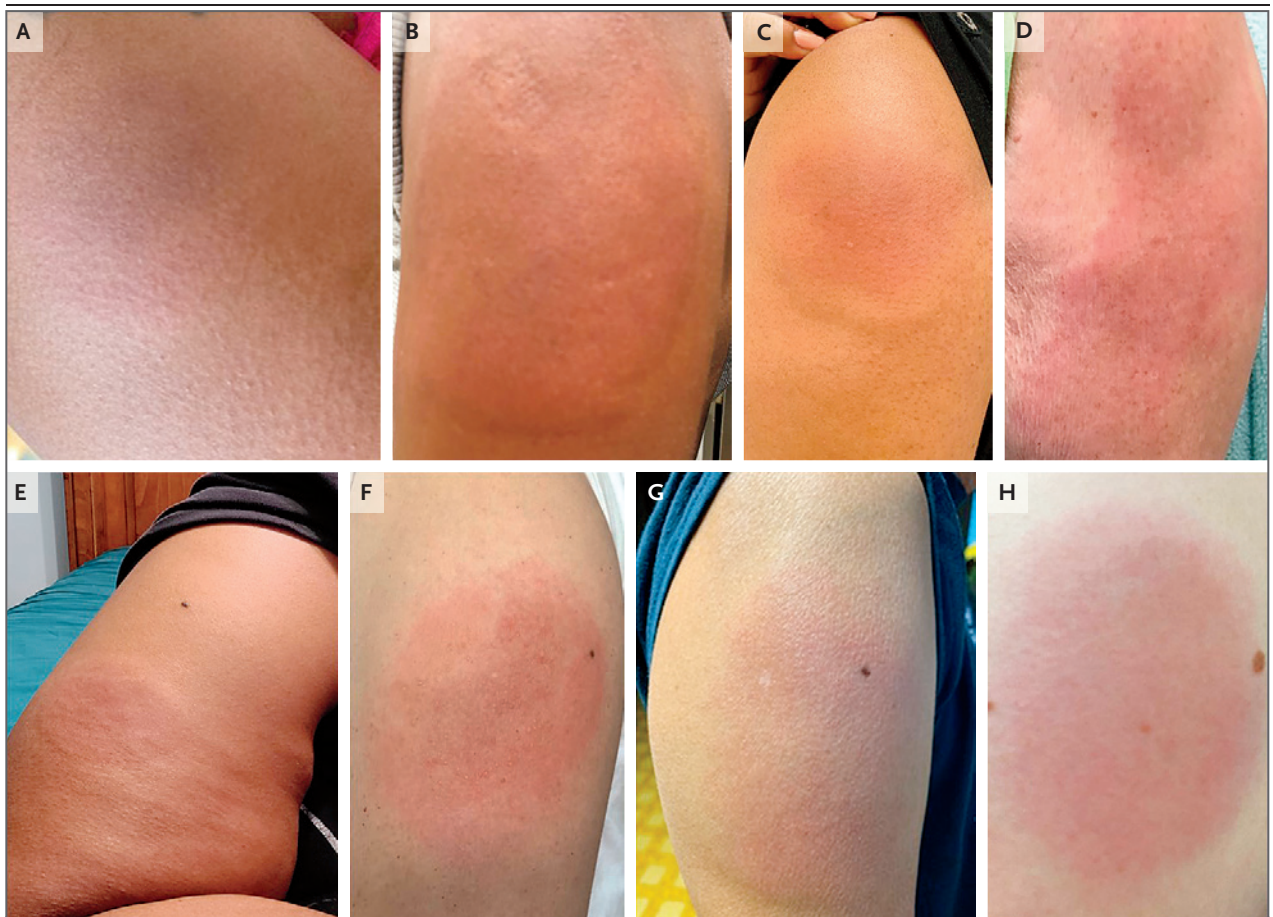


## CORRESPONDENCE

## Delayed Large Local Reactions to mRNA Covid-19 Vaccines in Blacks, Indigenous Persons, and People of Color

**TO THE EDITOR:** Blumenthal et al.<sup>1</sup> report delayed large local reactions in 12 patients who had received the mRNA-1273 vaccine against severe acute respiratory syndrome coronavirus 2 (SARS-CoV-2), the virus that causes coronavirus disease 2019 (Covid-19). Baeck et al.<sup>2</sup> report a similar reaction

to the BNT162b2 vaccine. The majority of these patients with delayed large local reactions and those whose cases have been reported elsewhere<sup>3,4</sup> have been White. Alvarez-Arango et al.<sup>5</sup> note the importance of diverse images of dermatologic findings to mitigate cognitive biases and to bet-



**Figure 1.** Delayed Large Local Reactions to mRNA Vaccines in Blacks, Indigenous Persons, and People of Color.

Shown are delayed large local reactions in a 41-year-old Black woman (Panel A), in a 51-year-old Black woman (Panel B), in a 44-year-old Black woman (Panel C), and in a 69-year-old woman of mixed race (Asian and White; Panel D), all of whom had received the first dose of the mRNA-1273 vaccine against SARS-CoV-2. Also shown are delayed large local reactions in a 41-year-old Black woman who had received the first dose of the BNT162b2 vaccine (Panel E), in a 60-year-old Asian woman who had received the first dose of the mRNA-1273 vaccine (Panel F), in a 73-year-old Asian man who had received the second dose of the mRNA-1273 vaccine (Panel G), and in a 21-year-old Hispanic woman who had received the first dose of the mRNA-1273 vaccine (Panel H).

ter prepare clinicians to recognize and address cutaneous reactions in the diverse patients we serve. We therefore present a case series of delayed large local reactions to messenger RNA (mRNA) vaccines against SARS-CoV-2 in recipients who are Black, Indigenous, or People of Color (BIPOC).

From February 10, 2021, through April 23, 2021, a total of 1422 reports of postvaccination reactions were submitted to a Covid-19 vaccine allergy case registry (<https://allergyresearch.massgeneral.org>). Of these reactions, 510 (36%) were delayed large local reactions that were reported by patients (64%) and clinicians (36%). The mean ( $\pm$ SD) age of the patients with delayed large local reactions was  $50\pm 15$  years (range, 21 to 91), and the majority were women (472 [93%]). Delayed large local reactions were reported after the receipt of the mRNA-1273 vaccine in 459 patients (90%), after the receipt of the BNT162b2 vaccine in 35 (7%), and after the receipt of other or unknown Covid-19 vaccines in 16 (3%).

The reports of delayed large local reactions after the receipt of Covid-19 vaccines included 55 events (11%) in BIPOC patients (Fig. 1). The reactions were reported in patients who were Asian (27 [5%]); of mixed race, which included American Indian–Alaska Native and Native Hawaiian–Pacific Islander (22 [4%]); and Black (6 [1%]). Six of these patients (11%) were Hispanic. A majority of these delayed large local reactions occurred after the receipt of the first vaccine dose (in 53 patients [96%]) and after the receipt of the mRNA-1273 vaccine (in 47 [85%]). The mean time from vaccination until the onset of the reaction was  $8\pm 2$  days (range, 4 to 14). Eleven patients (20%) had cutaneous reactions other than at the injection site, such as diffuse itching, hives or other rash, or angioedema.

Delayed large local reactions may be less commonly recognized or reported in BIPOC vaccine recipients than in White recipients. Such

reactions may result in vaccine hesitancy or incomplete vaccination; as such, proactive outreach is needed to increase education regarding these reactions across diverse communities. We hope that this letter encourages additional research and communication regarding cutaneous vaccine reactions, including delayed large local reactions, in BIPOC recipients.

Upeka Samarakoon, Ph.D., M.P.H.

Massachusetts General Hospital  
Boston, MA

Santiago Alvarez-Arango, M.D.

Johns Hopkins School of Medicine  
Baltimore, MD

Kimberly G. Blumenthal, M.D.

Massachusetts General Hospital  
Boston, MA  
kblumenthal@mgh.harvard.edu

The content of this letter is solely the responsibility of the authors and does not necessarily represent the official views of the National Institutes of Health (NIH) or Massachusetts General Hospital.

Supported by a grant (K01AI125631, to Dr. Blumenthal) from the NIH and by a grant (to Dr. Blumenthal) from the Department of Medicine Transformative Scholar Program at Massachusetts General Hospital.

Disclosure forms provided by the authors are available with the full text of this letter at [NEJM.org](http://NEJM.org).

This letter was published on June 9, 2021, at [NEJM.org](http://NEJM.org).

1. Blumenthal KG, Freeman EE, Saff RR, et al. Delayed large local reactions to mRNA-1273 vaccine against SARS-CoV-2. *N Engl J Med* 2021;384:1273-7.
2. Baeck M, Marot L, Belkhir L. Delayed large local reactions to mRNA vaccines. *N Engl J Med*. DOI: 10.1056/NEJMc2104751.
3. McMahon DE, Amerson E, Rosenbach M, et al. Cutaneous reactions reported after Moderna and Pfizer COVID-19 vaccination: a registry-based study of 414 cases. *J Am Acad Dermatol* 2021 April 7 (Epub ahead of print).
4. Johnston MS, Galan A, Watsky KL, Little AJ. Delayed localized hypersensitivity reactions to the Moderna COVID-19 vaccine: a case series. *JAMA Dermatol* 2021 May 12 (Epub ahead of print).
5. Alvarez-Arango S, Ogunwole SM, Sequist TD, Burk CM, Blumenthal KG. Vancomycin infusion reaction — moving beyond “Red Man Syndrome.” *N Engl J Med* 2021;384:1283-6.

DOI: 10.1056/NEJMc2108620

Correspondence Copyright © 2021 Massachusetts Medical Society.